

Portal Vein Thrombosis Complicating Islet Transplantation in a Recipient with the Factor V Leiden Mutation

A 31-year-old Native American/white female with Type 1 diabetes mellitus of 26 years duration enrolled in the international multicenter trial of the Immune Tolerance Network (NS01) to replicate the Edmonton Protocol for islet transplantation. She used oral contraceptives. She had undergone two prior islet transplant procedures complicated by sirolimus induced mucositis, diarrhea, and anemia, treated with replacement of sirolimus with mycophenolate mofetil. She received a third transplant of 314,039 islets (4,906 islet equivalents per kg) with a purity of 30% in 9 ml of packed-cell volume in two aliquots through a 5-Fr cholangiogram catheter in the right branch of the portal vein. Each aliquot contained heparin, 35 u/kg of patient body weight. After one hour, she developed abdominal pain, hypotension, and anemia. Enoxaparin was withheld. An abdominal ultrasound on postprocedure day 1 revealed a perihepatic fluid collection consistent with blood and patent hepatic vessels without evidence of thrombosis. She received 4 units of packed red blood cells over 48 hours, and her hemoglobin stabilized.

An abdominal ultrasound on post-procedure day 7 demonstrated a nonocclusive thrombus in the right portal vein, 30 mm in length (Fig. 1). She was anticoagulated with heparin and then warfarin. Serial ultrasounds revealed resolution of the thrombosis by 12 weeks after the event. A thrombophilia evaluation for antithrombin III, protein C and S, anticardiolipin antibodies, homocysteine, prothrombin gene mutation, and Factor V Leiden (FVL) revealed heterozygosity for the FVL mutation, and negative or normal otherwise. Subsequent genetic analysis of her mother revealed heterozygosity for FVL.

Portal vein thrombosis after islet allotransplantation has been reported previously (1–3). The perceived risks include transplantation of large packed cell volumes of partially purified islets (1), technical difficulties including intraportal injection of Gelfoam (2), and repeated transplant procedures (3). Thrombophilia has not been previously identified as a risk factor.

Our subject had several identified risks for development of portal vein thrombosis: infusion of larger than average packed cell volume (although within

protocol guidelines), third transplant, anticoagulation discontinued after infusion of the islets because of bleeding complications, and use of oral contraceptives. Gelfoam was not used with any procedure.

Approximately 5% of whites are heterozygous for the FVL mutation, the most common cause of hereditary thrombophilia (4). For individuals presenting with venous thrombosis, FVL occurs in 11–20% of those in all age groups and 50% of individuals under 50 years of age (5). Heterozygosity for this mutation produces a 7-fold relative risk of venous thrombosis. Our patient used oral contraceptives. The risk of venous thrombosis with both oral contraceptive use and the Factor V Leiden mutation is increased more than 30-fold compared with neither risk factor (6).

Given the relatively high prevalence of this mutation in the general population (5%), we recommend thrombophilia screening for potential islet transplant recipients. If transplantation is performed in such individuals, the procedure should be optimized by using high purity isolations, limiting the packed cell volume to less than 3 ml, limiting bleeding, avoiding oral contraceptives, and using prolonged anticoagulation prophylaxis.

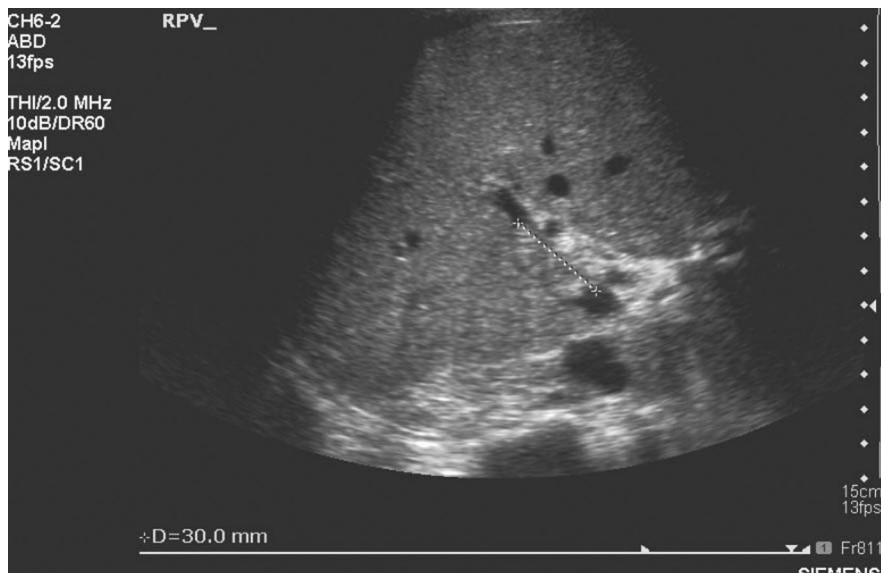


FIGURE 1. Hepatic ultrasound of the portal vein showing a 30 mm thrombus.

Daniel C. Brennan
M. Brendan Shannon
Matthew J. Koch

Kenneth S. Polonsky
Department of Medicine
Washington University School of Medicine
St. Louis, MO

Niraj Desai
Department of Surgery
Washington University School of Medicine
St. Louis, MO

James Shapiro
Department of Surgery
University of Alberta
Edmonton, Alberta, Canada

The National Institute of Allergy and Infectious Diseases sponsored this work. Additional funds were provided by the National Institute of Diabetes (NIH M01-RR 0036) and the

American Society of Transplantation (Young Investigator Award, DCB).

Address correspondence to: Daniel C. Brennan, M.D., Washington University School of Medicine, 660 S. Euclid Ave, Campus Box 8126, St. Louis, MO 63110. E-mail: brennand@msnotes.wustl.edu.

Received 5 February 2004. Accepted 9 February 2004.

Copyright © 0 by Lippincott Williams & Wilkins
ISSN 0041-1337/0-2000/00-173
DOI: 10.1097/01.TP.0000128332.71657.EA

REFERENCES

1. Shapiro AM, Lakey JR, Rajotte RV, et al. Portal vein thrombosis after transplantation of partially purified pancreatic islets in a combined human liver/islet allograft. *Transplantation* 1995; 59: 1060.
2. Ryan EA, Lakey JR, Rajotte RV, et al. Clinical outcomes and insulin secretion after islet transplantation with the Edmonton protocol. *Diabetes* 2001; 50: 710.
3. Casey JJ, Lakey JR, Ryan EA, et al. Portal venous pressure changes after sequential clinical islet transplantation. *Transplantation* 2002; 74: 913.
4. Ridker PM, Miletich JP, Hennekens CH, et al. Ethnic distribution of factor V Leiden in 4047 men and women. Implications for venous thromboembolism screening. *JAMA* 1997; 277: 1305.
5. Bauer K. Activated protein C resistance and Factor V Leiden. UpToDate 2003 Online (www.uptodate.com): 11.2.
6. Vandenbroucke JP, Koster T, Briet E, et al. Increased risk of venous thrombosis in oral-contraceptive users who are carriers of factor V Leiden mutation. *Lancet* 1994; 344: 1453.